

LTL-468 datasheet

Origin	Primary human ovarian cancer	Histopathology	Clear cell adenocarcinoma
Year of establishment	2011	Doubling time	7 days (subrenal capsule grafting site)
Local invasion	No	Metastasis	No

The LTL-468 was developed from a patient's primary ovarian cancer (high grade clear cell carcinoma). Histopathologically, it closely resembles the patient's cancer (Figs. 1, 2). When grafted under the renal capsules of SCID mice, the LTL-468 shows no local invasion or distant metastasis.

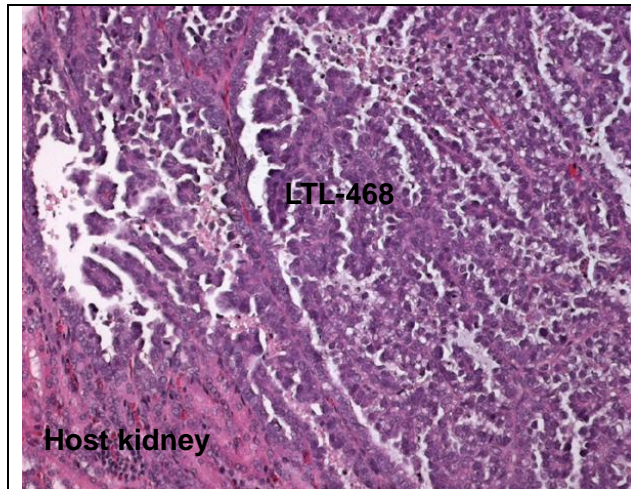


Fig 1. H&E stained LTL-468 tissue sections

The LTL-468 shows histopathological characteristics similar to those of the patient's cancer tissue before grafting (Fig 2). (200x)

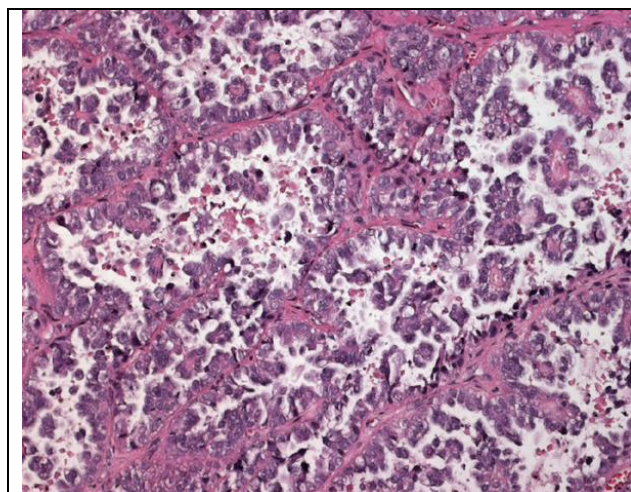


Fig. 2. Patient's cancer tissue before grafting.

Major histopathological characteristics:

- High grade clear cell carcinoma
- Tumor cells form tubular structure with fine papillae projecting into the lumina.
- The tumor cells containing clear cytoplasm and distinct cell membranes. (200x)

Genetic and epigenetic characteristics

Tumor line tissue (in Tissue Microarrays) for IHC and ISH is in place for screening potential targets upon request.

Applications

1. Pre-clinical evaluation of existing and potential anticancer drugs. Examination of drug efficacy on tumor growth, cell death (apoptosis, necrosis), tissue invasion, metastasis (in combination with metastatic tumor lines) and angiogenesis.
2. Discovery of potential therapeutic targets and/or biomarkers for drug sensitivity.
3. Study of mechanisms underlying tumor growth, progression and metastasis (in combination with metastatic tumor lines).

For more information, please contact us by email: LTL@bccrc.ca or phone: (604) 675 8013