

LTL-026 datasheet

Origin	Human lymphoma	Histopathology	diffuse large B-cell lymphoma (DLBCL)
Year of establishment	2006	Doubling time	5.8 days (sub-renal)
Local invasion	Yes	Metastasis	Yes
Drug sensitivity	CDDP 2.5 mg/kg + Gemcitabine 120mg/kg (T/C = 13.33%, responder) ; SAHA (vorinostat) 100mg/kg (T/C = 63 %, non-responder)		

The LTL-026 was developed from a patient's diffuse large B-cell lymphoma. When grafted under the renal capsules of SCID mice, the LTL-026 shows local invasion into adjacent host kidney parenchyma. Metastasis to mouse thymus lymph nodes was observed.

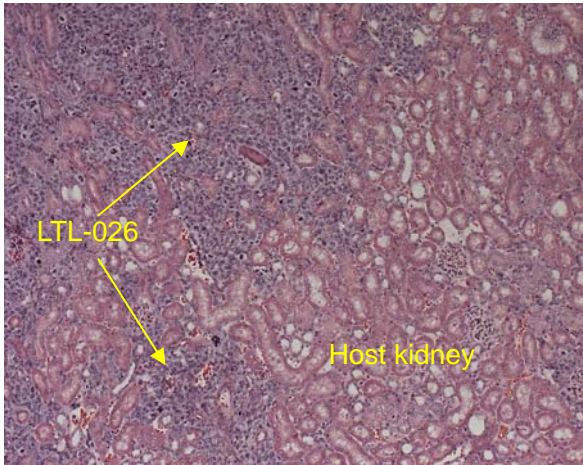


Fig. 1. H&E stained LTL-026 tissue sections.

When grafted under the renal capsules of SCID mice, the LTL-026 invades into adjacent mouse kidney.

For more information, please contact us by email: LTL@brrcr.ca or phone: (604) 675 8013